

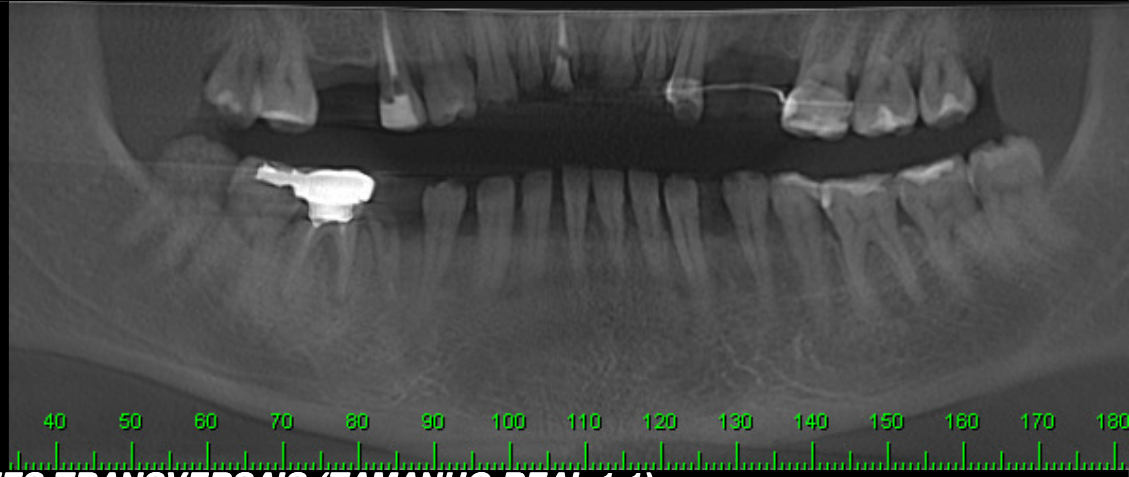
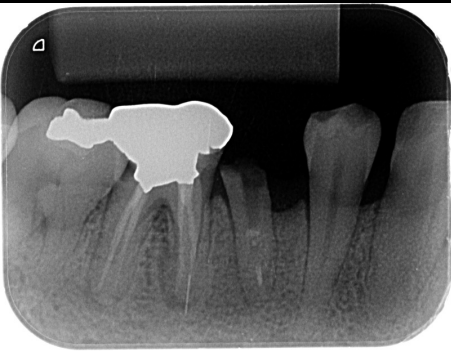


TOMOGRAFIA COMPUTADORIZADA POR FEIXE CONICO

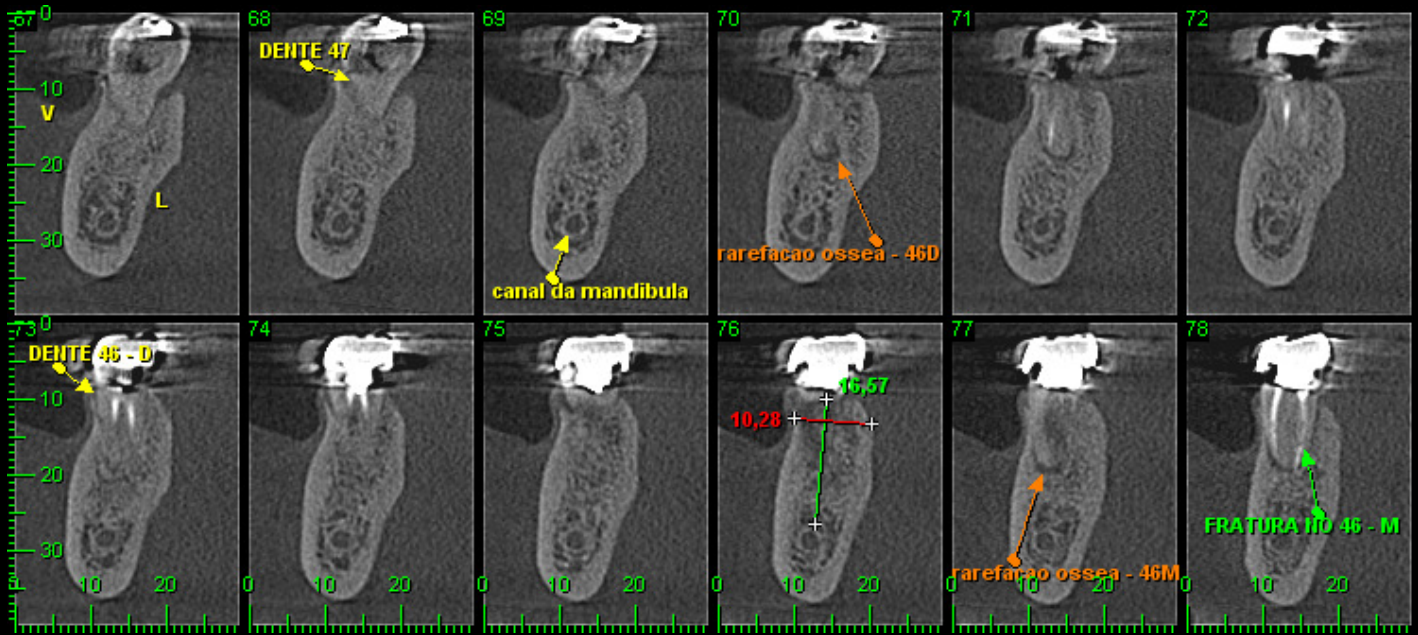
FINALIDADE DO EXAME - FRATURA RADICULAR

RECONSTRUCAO PANORAMICA - TAMANHO REAL

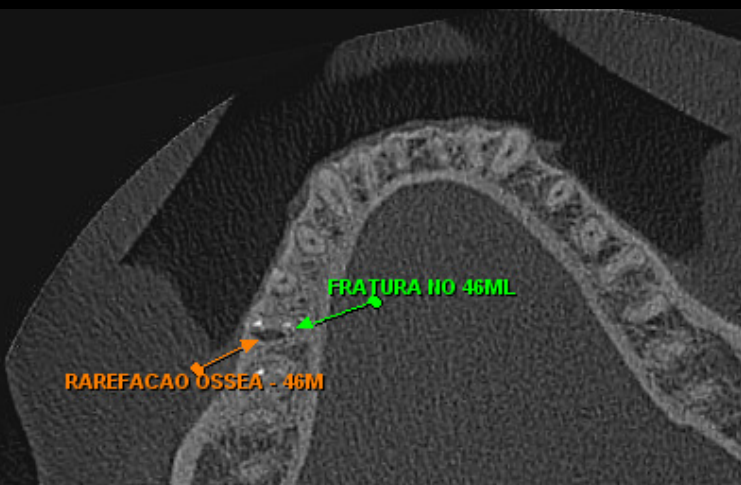RADIOGRAFIA PERIAPICAL DO DENTE 45



CORTES TRANSVERSAIS (TAMANHO REAL 1:1)



CORTE AXIAL



CORTE SAGITAL

